Taylor & Francis
Taylor & Francis Group

Journal of Plastic Surgery and Hand Surgery

ISSN: 2000-656X (Print) 2000-6764 (Online) Journal homepage: http://www.tandfonline.com/loi/iphs20

Breast reconstruction following nipple-sparing mastectomy: clinical outcomes and risk factors related complications

Rosaria Laporta, Benedetto Longo, Michail Sorotos, Alessio Farcomeni, Caterina Patti, Maria Rosaria Mastrangeli, Corrado Rubino & Fabio Santanelli di Pompeo

To cite this article: Rosaria Laporta, Benedetto Longo, Michail Sorotos, Alessio Farcomeni, Caterina Patti, Maria Rosaria Mastrangeli, Corrado Rubino & Fabio Santanelli di Pompeo (2017): Breast reconstruction following nipple-sparing mastectomy: clinical outcomes and risk factors related complications, Journal of Plastic Surgery and Hand Surgery, DOI: 10.1080/2000656X.2017.1303500

To link to this article: http://dx.doi.org/10.1080/2000656X.2017.1303500

Published online: 20 Mar 2017.

JOURNAL OF PLASTIC SURGERY AND HAND SURGERY, 2017
http://dx.doi.org/10.1080/2000656X.2017.1303500

ORIGINAL ARTICLE

Breast reconstruction following nipple-sparing mastectomy: clinical outcomes and risk factors related complications

Rosaria Laporta[a], Benedetto Longo[a], Michail Sorotos[a], Alessio Farcomeni[b], Caterina Patti[a], Maria Rosaria Mastrangeli[a], Corrado Rubino[c] and Fabio Santanelli di Pompeo[a]

[a]Plastic Surgery Department, Sant'Andrea Hospital, School of Medicine and Psychology, "Sapienza" University of Rome, Rome, Italy; [b]Department of Public Health and Infectious Diseases, "Sapienza" University of Rome, Rome, Italy; [c]Department of Medicine and Surgery, Plastic Surgery Unit, University of Salerno, Azienda Ospedaliera Universitaria OO.RR. San Giovanni di Dio e Ruggi d'Aragona, Salerno, Italy

ABSTRACT

Background: The aim of this study was to investigate clinical outcomes and risk factors related complications in patients who had undergone nipple-sparing mastectomy (NSM) followed by implant-based or autologous reconstruction.

Methods: Between 2004–2014 a single-institution retrospective review was collected on NSMs reconstruction. Patient demographics, comorbidities, breast morphological factors, type and timing of radiotherapy, type of incision, reconstruction type and timing, implant volume and complications were collected.

Results: A total of 288 patients had undergone 369 NSMs, 81 (28.1%) of which were bilateral while 207 (71.9%) unilateral. One-hundred mastectomies were performed for prophylactic purposes whereas 269 were therapeutics. Thirteen (4.5%) patients were active smokers, while 2 (0.7%) were diabetics. Fifty-five breasts (14.9%) were previously irradiated and average time elapsed between radiotherapy and NSM was 9-year, (range, 5–15 yrs). Total complication rate was 13.5% at mean follow-up of 47.98 months (range, 6–114 months). Partial-thickness and full-thickness mastectomy skin flap and NAC necrosis occurred in 39 (78%) and in 10 (20%) breasts, respectively. Previous radiotherapy and implant volume were significant predictors of complications (OR: 10.14, 95% CI: 3.99–27.01; OR $\times$ 100 g: 3.13, 95% CI: 1.64–6.33). Overall mastectomy type incision was not predictive of complications ($p = .426$). No association was observed between radiotherapy and mastectomy type access ($p = .349$).

Conclusions: From our experience NSM followed by implant-based and autologous reconstruction had a relative high rate of complications comparable to previous reports. Despite this, it should be carefully offered to patients in whom potential risk factors are identified.

ARTICLE HISTORY
Received 24 May 2016
Revised 6 July 2016
Accepted 23 February 2017

KEYWORDS
Nipple-sparing mastectomy; radiotherapy; breast cancer; surgical incision; smoking; risk factors

Introduction

The evolution of breast reconstruction techniques has as a result an improvement of the aesthetic outcomes, and nipple-sparing mastectomy (NSM) has been one of the major contributing factors. Despite early concerns regarding the risk of loco regional recurrence, there is a growing body of evidence claiming its oncological safety [1–4]. The patient selection criteria have significantly changed; however, the tumor size, nodal status, and the distance from the nipple are the parameters that are most frequently adopted by breast surgeons. The ideal candidate has small-moderate, non-ptotic or minimally ptotic breasts. NSM can be performed through a radial, transverse periareolar ("omega"), lateral, double concentric periareolar, circum-areolar, vertical infraareolar, inframammary fold (IMF) or inferolateral IMF incision with or without an axillary incision. These different approaches have associated complications and unfortunate results such as infection, implant removal, skin loss, breast contour deformity, capsule formation, and visible scars in the upper half of the breast. Wound healing complications and nipple-areola complex (NAC) necrosis are reported ranging from 0% to 29% but most series showed less than 10% [4–6]. Although the anatomical criteria for NSM have been expanded and shown to be a viable option in patients who have undergone prior mastopexy or reduction, the effects of radiation therapy remain unclear [7]. The aim of this study was to investigate risk factors related complications and clinical outcomes in NSMs followed by both implant-based and autologous reconstruction.

Patients and methods

A single-institution retrospective chart review was collected on all NSMs followed by implant-based or autologous reconstruction performed from May 2004 to December 2014. In our department, NSM was offered to eligible women with small to medium breast size, either for prophylactic or oncological purposes. Contraindications for NSM were lesions within 2 cm from the NAC, multicentric disease, lesions >3 cm and prominent lymphovascular invasion. Positivity for

CONTACT Fabio Santanelli di Pompeo fabio.santanelli@uniroma1.it Via di Grottarossa 1035-1039, 00189 Rome, Italy

malignancy after intraoperative frozen section of the retroareolar ducts excluded patients from this study to avoid any misleading in data interpretation. The oncological indication was changed from NSM to skin-sparing mastectomy.

NSM was performed to remove the breast tissue through 4 different access incisions: inframammary fold (IMF), inferolateral IMF, hemi-periareolar and omega-pattern. The reconstructive option offered to each patient was carefully evaluated on the basis of patient' characteristic, desires and expectation, medical condition, availability of abdominal tissue or other autologous donor site tissue.

Complications were defined as infection requiring intravenous antibiotics, partial and full-thickness mastectomy skin flap and NAC necrosis resulting in expander/implant loss, hematoma, seroma and flap loss. Predictive variables included mastectomy type access, patient age, body mass index (BMI), comorbidities (diabetes mellitus, hypertension, and dyslipidemia), smoking history, breast morphological factors such as sternal notch to nipple distance and degree of ptosis (grade 0, 1, 2, 3, pseudoptosis); mastectomy weight; type and timing of radiotherapy, type and timing of reconstruction and implant volume. A correlation between preexisting breast scar from lumpectomy/quadrantectomy and mastectomy type access in irradiated breast was also evaluated.

Statistical analyses

Statistical analyses were performed using R version 3.0.2 (R Development Core Team, Vienna, Austria). Age, BMI, degree of ptosis, incision type access, type of reconstruction, radiotherapy timing, mastectomy weight, implant volume, type of radiotherapy, smoking and presence of comorbidities were considered as possible predictors. Additionally, sternal notch to nipple distance was measured as a discrete continuous variable.

Univariate and multivariate logistic regression was performed to investigate associations between predictors and the outcome. A p values of below 0.05 was considered as significant. Univariate analysis was also performed to obtain odds ratios and 95% confidence intervals. In order to satisfy Harrel's 20:1 rule we selected at most two predictors. We proceeded first by selecting the two variables we deemed to be most likely to be related to the outcome. These were indeed significant. The model has been confirmed with best-subset selection and validated through Hosmer-Lemeshow test.

Results

The mean age of the patients was 47.6 years (range 32–60 years) and the mean BMI was 25.5 kg/m^2 (range 20–31 kg/m^2). Thirteen (4.5%) patients were active smokers at the time of the operation, while 2 (0.7%) patients were affected by diabetes.

A total of 288 patients had undergone 369 NSMs, 81 (28.1%) of which were bilateral while 207 (71.9%) unilateral. Reconstructive methods used included autologous tissue [deep inferior epigastric perforator (DIEP), superficial inferior epigastric artery (SIEA) flap, latissimus dorsi (LD) flap and lipofilling, thoracodorsal artery perforator (TDAP) flap, lipofilling (total autologous reconstruction with fat tissue)] in 173 breasts, direct implant in 24 breasts, two-stage reconstruction with expander/prosthesis placement in 44 breasts, while mixed reconstruction (LD flap and prosthesis) in 128 breasts. One-hundred mastectomies were performed for prophylactic purposes whereas 269 were therapeutics.

Overall reconstructions were performed through IMF incision in 61 (16.5%) cases, inferolateral IMF incision in 140 (38%) cases, hemi-periareolar incision in 64 (17.3%) cases, while omega pattern was used in 104 (28.2%) cases.

Fifty-five breasts (14.9%) were previously irradiated and average time elapsed between radiation therapy and NSM was 9-year, ranging from 5 to 15 years.

In irradiated breasts, the previous lateral/medial radial scar was converted in omega pattern in 32 cases, the previous supero-lateral circum-areolar scar was extended as an inferolateral IMF in 5 cases while the previous hemi-periareolar incision was extended as lateral radial incision in 18 cases (Figures 1 and 2). The patient characteristics and the reconstructive methods are summarized in Table 1.

Postoperative complications

A total of 50 complications occurred (13.5%) (Table 2). One case (2%) of infection was observed in direct implant reconstruction, while no cases of seroma or hematoma were observed. A partial thickness mastectomy skin flap and NAC necrosis occurred in 39 (78%) breasts, 19 of which were reconstructed using autologous tissue, 13 using LD flap and implant, 6 direct implant and 1 case using expander/prosthesis reconstruction. All 39 breasts were managed conservatively with repeated dressings in outpatient clinic.

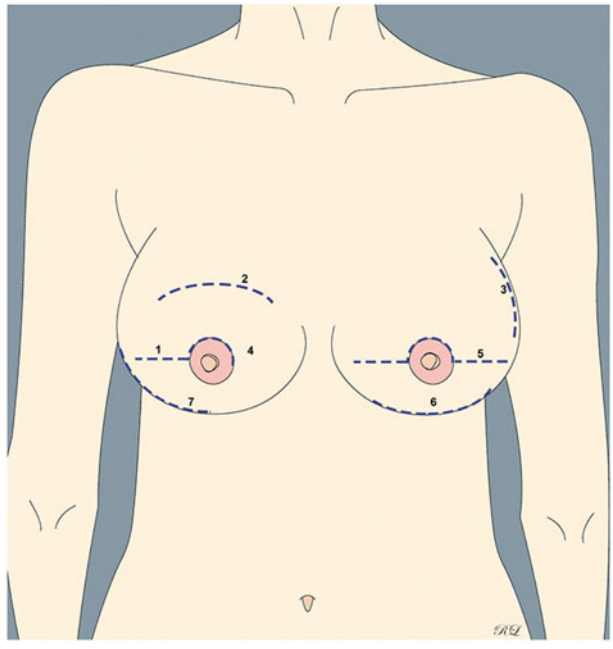

Figure 1. Incision types: 1 = radial incision, 2–3 = circum-areolar incision, 4 = hemi-periareolar incision, 5 = omega pattern, 6 = inframammary fold incision, 7 = inferolateral inframammary fold incision.

Conversely, a full-thickness mastectomy skin flap and NAC necrosis occurred in 10 cases (20%), 2 of which had autologous tissue reconstruction, 3 cases mixed reconstruction and 5 cases were reconstructed by the use of implant.

The treatment involved debridement and a full thickness skin-graft followed by a single fat-graft session for aesthetic refinements. Five cases that were reconstructed by the use of implant required latissimus dorsi flap 6-month after primary surgery because of the implant exposition.

One case of fat necrosis and 2 cases of partial flap necrosis occurred in DIEP flap reconstruction. Fat necrosis was defined as ischemic tissue loss characterized by subcutaneous firmness of 2 to 5 cm in diameter while partial flap loss was defined as tissue loss greater than 10% of the flap or fat necrosis greater than 5 cm in diameter. Secondary revision procedures (excision of the necrotic tissue and subsequent lipofilling sessions) succeeded in the creation of an aesthetically acceptable reconstructive result. Two cases of donor site seroma were observed in LD flap breast reconstruction requiring aspiration and pressure dressings.

Twelve patients received postoperative radiotherapy, 4 of whom had undergone autologous tissue reconstruction and 6 mixed reconstruction and 2 expander/prosthesis placement. Capsular contracture was observed in 8 cases of LD flap and implant reconstruction, in 12 cases of expander/prosthesis placement and in 2 cases of direct implant reconstruction at mean follow-up of 47.98 months, range 6–114 months. Implant replacement were performed in 14 cases while lipofilling session was carried out in 12 cases (Table 3).

Surgical risk factors

The complication rate was analyzed by the reconstruction and incision type (Table 4).

The hemi-periareolar incision was associated with the highest rate of complication [22 out of 64 cases (34.4%)], whereas the inferolateral IMF incision had the lowest complication rate [9 out of 140 cases (6.4%)]. Both incision types were associated with a partial thickness mastectomy skin flap and NAC necrosis including 10 (45.5%) and 8 (88.9%) cases, respectively. A full-thickness mastectomy skin flap and NAC necrosis were observed in the hemi-periareolar incision in 12 out of 22 cases (54.5%) and in the supero-lateral circum-areolar incision extended to the inferolateral IMF in 3 out of 9 cases (33.3%).

At multivariate regression, previous radiotherapy was a significant predictor of complications (OR: 10.14, 95% CI: 3.99–27.01). Implant volume was also a positive predictor with OR: 3.13, 95% CI: 1.64–6.33 for every 100 g of volume increase (Table 5) (Figures 3–9). The model was validated through Hosmer-Lemeshow test ($p = .263$). Overall the type

Table 1. Patient characteristics and reconstructive methods.

Patient population	
No. of patients	288
No. of reconstructions	369
Follow-up period (month)	
Mean	47.98
Range	6–114
Demographics and risk factors	
Age (yr)	
Mean	47.6
Range	32-60
BMI (kg/m^2)	
Mean (Standard Deviation)	25.5 (2.86)
Range	20–31
Smoking	13
Diabetes	2
Previous Radiotherapy (breasts)	55
Implant volume (g)	
Mean	345.13
Range	195–520
Type of reconstruction	
Autologous	
DIEP flap	104
SIEA flap	5
LD flap and lipofilling	11
TDAP flap	5
Lipofilling	48
Implant	
Implant and acellular dermal matrix	24
Expander/Prosthesis	44
Mixed	
LD flap and prosthesis	128
Indication	
Prophylactic	100
Therapeutic	269
Mastectomy incision	
Inferolateral IMF	140
IMF	61
Omega pattern	104
Hemi-periareolar	64

IMF: inframammary fold; DIEP: deep inferior epigastric perforator flap; SIEA: superficial inferior epigastric artery flap; LD: latissimus dorsi flap; TDAP: thoracodorsal artery perforator flap. Lipofilling reconstruction means total autologous reconstruction of the breast by the use of fat tissue.

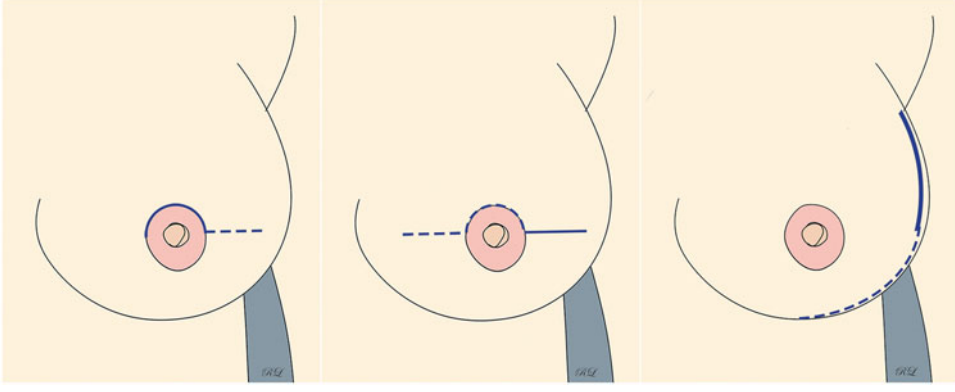

Figure 2. Extension of a preexisting scar. (Left) hemi-periareolar incision was extended as a radial lateral scar; (Center) lateral/medial radial incision was converted in omega pattern; (Right) supero-lateral circum-areolar incision was extended as inferolateral inframammary fold incision.

Table 2. Complications divided by reconstruction type.

Type of reconstruction	Partial thickness Mastectomy skin flap and NAC necrosis No. (%)	Full-thickness Mastectomy skin flap and NAC necrosis No. (%)	Infection No. (%)
Autologous			
DIEP flap	18/104 (17.3)	2/104 (1.9)	–
SIEA flap	0/5 (0)	0/5 (0)	–
LD flap + lipofilling	0/11 (0)	0/11 (0)	–
TDAP flap	0/5 (0)	0/5 (0)	–
Lipofilling	1/48 (2.1)	0/48 (0)	–
Implant			
Implant and acellular dermal matrix	6/24 (25)	5/24 (20.8)	1/24 (4.1)
Expander/Prosthesis	1/44 (2.3)	0/44 (0)	–
Mixed			
LD flap + Prosthesis	13/128 (10.1)	3/128 (2.3)	–
Total	39(78)	10 (20)	1(2)

NAC: nipple areola complex; DIEP: deep inferior epigastric perforator flap; SIEA: superficial inferior epigastric artery flap; LD: latissimus dorsi flap; TDAP: thoracodorsal artery perforator flap. Lipofilling reconstruction means total autologous reconstruction of the breast by the use of fat tissue.

Table 3. Postoperative radiotherapy, related complications and treatment of choice divided by reconstruction type at long-term of follow-up.

Type of reconstruction	Postoperative radiotherapy No. (%)	Capsular contracture No. (%)	Implant replacement No. (%)	Lipofilling session No. (%)
Autologous				
DIEP flap	4/104 (3.8)	0/104 (0)	–	4/104 (3.8)
SIEA flap	0/5 (0)	0/5 (0)	–	–
LD flap + lipofilling	0/11(0)	0/11 (0)	–	–
TDAP flap	0/5 (0)	0/5 (0)	–	–
Lipofilling	0/48 (0)	0/48 (0)	–	–
Implant				
Implant and acellular dermal matrix	0/24 (0)	2/24 (8.3)	2/24 (8.3)	0/24 (0)
Expander/Prosthesis	2/44 (4.5)	12/44 (27.3)	8/44 (18.2)	4/44 (9)
Mixed				
LD flap + Prosthesis	6/128 (4.7)	8/128 (6.2)	4/128 (3.1)	4/128 (3.1)
Total	12/369 (3.2)	22/196 (11.2)	14/196 (7.1)	12/369 (3.2)

DIEP: deep inferior epigastric perforator flap; SIEA: superficial inferior epigastric artery flap; LD: latissimus dorsi flap; TDAP: thoracodorsal artery perforator flap. Of note, Implant loss was a result of the full-thickness mastectomy skin flap and NAC necrosis. Lipofilling reconstruction means total autologous reconstruction of the breast by the use of fat tissue.

Table 4. Number of complications divided by reconstruction and incision type.

	Type of incision			
Type of reconstruction	Inferolateral IMF	Hemi-periareolar	Omega pattern	IMF
Autologous				
DIEP flap	3	11	3	2
SIEA flap	0	0	0	0
LD flap + lipofilling	0	0	0	0
TDAP flap	0	0	0	0
Lipofilling	0	0	1	0
Implant				
Implant and acellular dermal matrix	5	1	6	1
Expander/Prosthesis Mixed	0	0	1	0
LD flap + Prosthesis	1	10	4	1
Total Number of Complications (No./%)	9/140 (6.4)	22/64 (34.4)	15/104 (14.4)	4/61 (6.6)

IMF: inframammary fold; DIEP: deep inferior epigastric perforator flap; SIEA: superficial inferior epigastric artery flap; LD: latissimus dorsi flap; TDAP: thoracodorsal artery perforator flap. Lipofilling reconstruction means total autologous reconstruction of the breast by the use of fat tissue.

of mastectomy incision was not predictive of complications ($p = .426$), even if from univariate analysis hemi-periareolar and omega pattern incisions were significantly related to complications ($p < .001$; $p = .047$). No association was also observed between previous radiotherapy and mastectomy type access ($p = .349$).

Type and timing of reconstruction and mastectomy weight (mean 439.56 g, range 220–700 g) were not significantly associated with mastectomy skin flap and NAC complication rate ($p = .994$; $p = .581$; $p = .487$). No statistical difference regarding complication rate was found between therapeutic and prophylactic mastectomy ($p = .08396$). Of the 55 breasts with available radiation oncology records, 30 received a dose of 50 Gy whole-breast irradiation followed by a tumor bed boost of 10 Gy while 25 patients received only a total dose of 50 Gy whole-breast irradiation. Patients who had undergone NSM within 5 years from radiotherapy were more exposed to complications (63.6%) rather than after

5 years (33.3%), although no correlation was observed between type and timing of radiotherapy and risk of complications ($p = .1293$) (Table 5).

Patient risk factors

At multivariate regression, there was no association between complications and age, BMI, smoking history and diabetes mellitus. No association was also observed regarding sternal notch to nipple distance and degree of ptosis ($p = .537$, $p = .486$) (Table 5).

Discussion

The transition from modified radical mastectomy to skin-sparing mastectomy and then to NSM has strained for an improved aesthetic outcome and quality of life for breast cancer patient while maintaining oncologic safety. Long-standing concerns about the post-operative viability of the skin and of the NAC are the main obstacles to the acceptance of NSM. In our series, NSM showed a relative high rate of complications (13.5%) comparable to the rate of complications of previous studies [8,9]. The health and overall viability of the nipple are likely dependent on the health and viability of the skin flaps dissected by the breast surgeon. Three surgeons at our institution compose the breast surgery group. As a result, since three different surgeons performed the NSMs, the mastectomy skin flap may have various thickness allowing different clinical and aesthetic results. However, the thickness may also vary between breasts, and between different parts of the same breast, and there is no good evidence that it is associated with obesity or age [10]. Thus the existence of a distinct layer of superficial fascia in the breast remains controversial as well as a specific universal thickness for mastectomy skin flaps cannot be recommended currently [10]. The surgeon must use skill and judgment to identify the plane dissection between the subdermal fat and the breast parenchyma. Because of the aforementioned and in order to reduce the complications rate, from 2004 to 2014 the team approach on breast surgical oncology and plastic surgery has led to advancements for successful surgical strategies and techniques in NSM. Breasts were always infiltrated with Klein modified solution [500 ml of saline, 20 ml 2% lidocaine, 10 ml of naropine (7.5 mg/ml) and 1 ml adrenaline (1 mg/ml)] along the marked incision and dissection planes. This was not performed with a pressurized system, but rather manually through a syringe. The volume injected was enough to cause a hydrodissection effect that aided in separating the dissection plane between the subcutaneous fat and the breast tissue in addition to providing hemostasis from the adrenaline. The plane of dissection was not obvious in every case and it was be quite irregular. Mastectomy was performed sharply with minimal use of electrocautery avoiding vigorous retraction and retractors with sharp teeth. A recent retrospective

Table 5. Univariate and multivariate statistical analyses.

Variable	OR	95% CI	*p*-value
Univariate Analysis			
Age	1.024	0.984–1.068	.249
Radiotherapy	9.633	4.947–18.982	**<.001**
Prosthesis Weight (100g)	3.313	1.806–6.388	**<.001**
BMI (kg/m^2)	1.293	1.069–1.560	**.007**
Mastectomy Weight (100g)	1.412	0.965–2.134	.086
Degree of Ptosis: 1	0.441	0.199–1.020	**.048**
Degree of Ptosis: 2	0.650	0.288–1.521	.306
No Smoking history	0.522	0.028–2.740	.536
Radiotherapy to Surgery (yrs)	0.861	0.735–0.991	**.046**
Radiotherapy type: Breast bed	0.667	0.224–1.941	.459
Sternal-Notch to Nipple Distance	0.575	0.245–1.369	.202
Expander/Prosthesis Reconstruction	0.765	0.214–2.161	.642
Mixed Reconstruction	1.015	0.491–2.062	.966
Implant Reconstruction	6.473	2.538–16.509	**<.001**
Hemiperiareolar Access	7.566	3.330–18.530	**<.001**
Omega Access	2.407	1.026–5.957	**.047**
IMF Access	1.014	0.266–3.252	.983
Therapeutic Mastectomy	0.470	0.198–0.990	.062
Multivariate Analysis			
Radiotherapy	10.14	3.99–27.01	<.001
Prosthesis Weight (100g)	3.13	1.64–6.33	<.001

BMI: body mass index.
From univariate analysis radiotherapy, implant volume for every 100 g of volume increase, implant reconstruction, hemi-periareolar and omega pattern incisions were significantly related to complications.

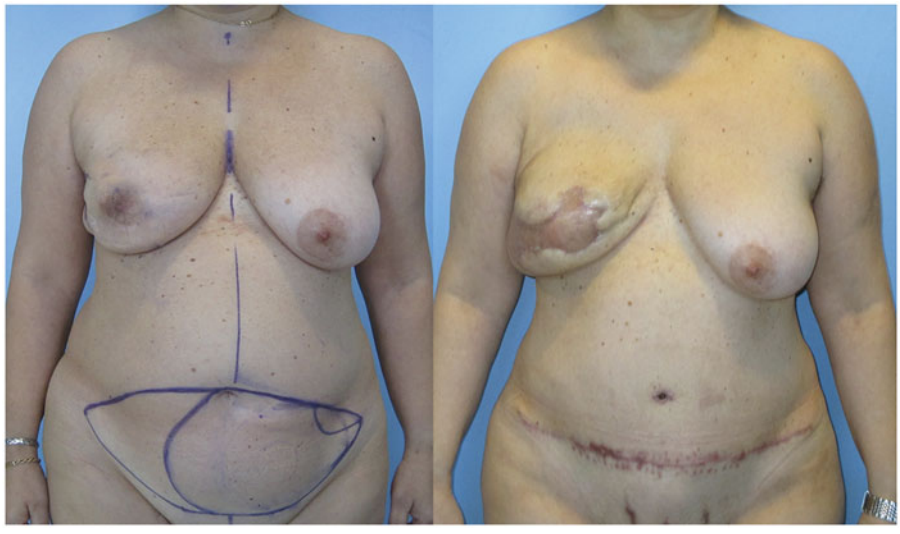

Figure 3. **Patient 3:** A 42-year-old woman had quadrantectomy of the right breast through supero-lateral circum-areolar incision. She received a dose of 50 Gy whole-breast irradiation followed by a tumor bed boost of 10 Gy. After 5 years, she had undergone right nipple-sparing mastectomy through inferolateral inframammary fold incision and immediate DIEP flap reconstruction. Full-thickness NAC and mastectomy skin flap necrosis of the inferior pole occurred requiring debridement and full-thickness skin-graft. Pre- and post-operative frontal view.

Figure 4. **Patient 3:** Pre- and post-operative oblique view.

Figure 5. **Patient 3:** Full-thickness NAC and mastectomy skin flap necrosis of the inferior pole occurred that required debridement and full thickness skin-graft.

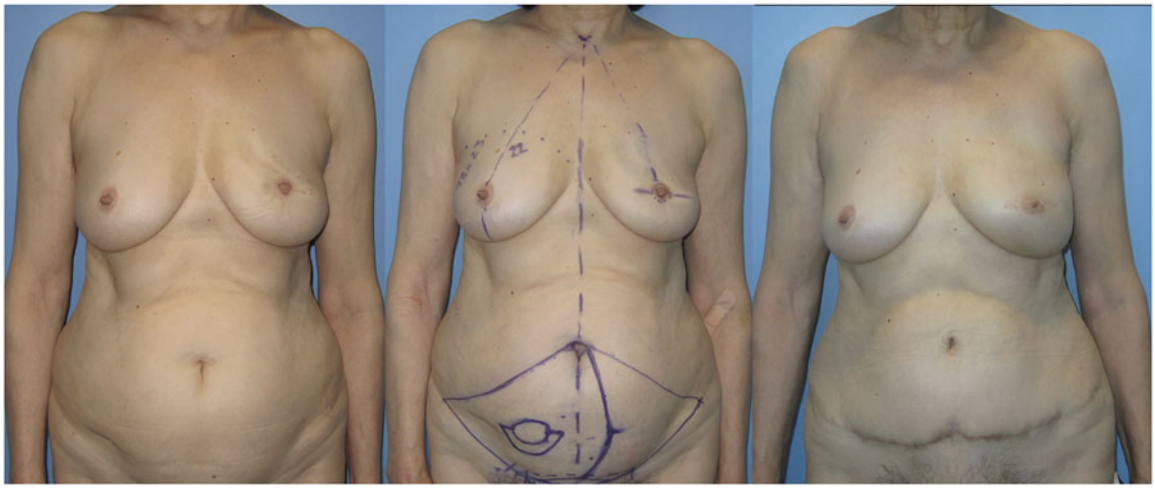

Figure 6. **Patient 8:** A 61-year-old woman had quadrantectomy of the left breast through lateral radial incision. She received a total dose of 50 Gy whole-breast irradiation. After 10 years, she had undergone left nipple-sparing mastectomy through omega pattern incision and immediate DIEP flap reconstruction. Pre- and post-operative frontal view.

Figure 7. **Patient 14:** A 41-year-old woman had quadrantectomy of the right breast through hemi-periareolar incision. She received a total dose of 50 Gy whole-breast irradiation. After 6 years, she had undergone right nipple-sparing mastectomy through extension of the hemi-periareolar incision with lateral radial incision and immediate DIEP flap reconstruction. Partial mastectomy skin flap and NAC necrosis occurred that required repeated dressings in outpatient clinic. (Left) Pre-operative frontal view. (Center) patient had undergone post-operative radiotherapy. (Right) at 12 months of follow-up areola tattoo was done.

Figure 8. **Patient 14:** Partial mastectomy skin flap and NAC necrosis occurred that required repeated dressings in outpatient clinic.

study by Chun et al. showed an increase in mastectomy flap necrosis with use of the tumescent technique, however, neither the composition of the solution nor the volumes injected were reported [11].

However, the type of incision has the potential to disrupt the blood supply of the breast skin and NAC. According with previous studies [8,9], overall the inferolateral IMF incision had the lower rate of complications while hemi-periareolar incision had the highest rate of complication.

Colwell et al. reported outcomes in their series of 500 NSMs, of which 42 had a history of preoperative radiation therapy associated with an odd ratio of 4.8 for NAC necrosis. Comparing patients who had one or more complications to those who did not have complications, a periareolar incision was associated with the highest rate of total complications, whereas the inferolateral IMF incision had the lowest rate of total complications and better aesthetic results because of favorable scar hidden on anterior view [8].

In the current study, the type of mastectomy incision was not predictive of complications, even if from univariate analysis hemi-periareolar and omega pattern incisions were significantly related to complications ($p < .05$). At multivariate regression, previous radiotherapy was a significant predictor of complications with an odd ratio of 10.14. No association was observed between previous radiotherapy and mastectomy type access ($p = 0.349$).

It should be noticed that if on any region of the breast a scar already exist, this should be used as access because of the already violated blood supply area. Epidermal atrophy, hyperkeratosis and incorporation of telangiectatic vessels, thin and flat papillary layer of the dermis, a hypocellular fibrotic dermis, sclerotic vessel changes, reduced number and atrophied pilosebaceous units are the main effects of radiotherapy. Impaired wound healing is believed to be caused by progressive fibrosis, depletion of parenchymal and stem cells, and release of bioactive cytokines [12].

The previous radial horizontal incision was converted in omega pattern incision in order to maximize the blood flow to the nipple. The previous hemi-periareolar incision was extended to a radial lateral one, rather than to an omega pattern, in order to preserve mostly the NAC blood supply. The previous supero-lateral circum-areolar incision was extended to an inferolateral IMF incision in order to not further damage the already violated blood supply. Even if it was not significant, this approach had a high rate of complications. Three (60%) of those 5 breasts had a full-thickness mastectomy skin flap and NAC necrosis with 2 cases of reconstruction failure. Conversely, the omega-pattern incision had the lowest complication rate (25%) compared to the hemi-periareolar incision (72.2%) and to the inferolateral IMF (60%) in previously irradiated breasts. The small case series of 55 irradiated breasts was a study limitation to give a definitive result on the correlation between incision type and previous radiotherapy. From our experience, in case of eventual NSM, the choice of the incision type during lumpectomy/quadrantectomy should be carefully evaluated because it is a determinant factor for the viability of the mastectomy skin flap and NAC. Currently at our institution, if previously

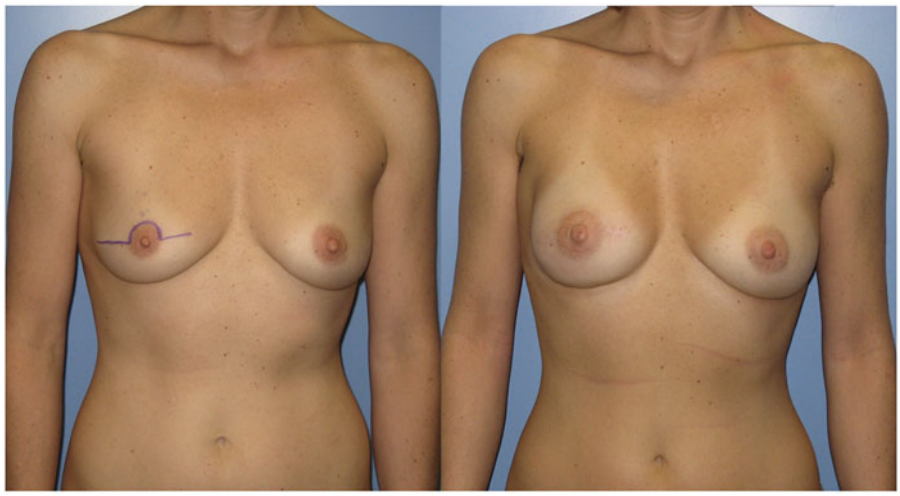

Figure 9. **Patient 21:** a 38-year-old woman had quadrantectomy of the right breast through lateral radial incision. She received a total dose of 50 Gy whole-breast irradiation. After 6 years, she had undergone right nipple-sparing mastectomy through omega pattern incision and immediate reconstruction with latissimus dorsi flap and prosthesis. Pre- and post-operative frontal view.

irradiated patients with supero-lateral circum-areolar incision following lumpectomy/quadrantectomy are oncologically eligible to NSM, we prefer to perform a NSM with a resection of skin ellipse including the previous scar and the inferior breast pole. Although the aesthetic result of a patch-like effect achieved with a flap is not optimal, this is preferable when compared to the high risk of necrotic complication and reconstruction failure.

Type and timing of reconstruction are a multifactorial decision, based on several factors including size and shape of the native breast, patient's demographic information, surgeon's preference and experience, and the quality of the mastectomy skin flaps. In our institution the autologous reconstruction is the first choice for breast cancer patients, while implant-based reconstruction is considered as a second choice. Although the implant-based reconstruction can be successfully performed in irradiated and non-irradiated patients as previously reported [9], we believe that the complication management may be easier in autologous reconstruction than in the implant one. If a mastectomy skin flap and NAC necrosis occur, in the latter can result in reconstruction failure that requires a secondary procedure increasing emotional distress of cancer patients. Type of reconstruction was not significantly associated with the complication rate, even if 5 out of 24 cases of direct implant reconstruction resulted in full-thickness mastectomy skin and NAC necrosis with a consequent implant loss.

No higher risk of complication was observed regarding sternal notch to nipple distance and degree of ptosis, probably because the NSM candidate patients did not have breast ptosis higher than the second degree.

There was no association between the mastectomy weight (mean 439.56 g, range 220–700 g) and the complication rate ($p = .487$). In the report by Woerdeman et al, the specimen weight >540 g more than the mean weight seemed to be associated with statistically significant odds ratios to develop complications [13]. Similar result was referred by Munhoz et al, even if the weight of the specimen was >380 g [14]. Chirappapha et al observed a trend of higher risk of necrosis but not significant in ptotic breast, with volume of breast removed $\geq$750 cm^3 [9], while Nahabedian et al reported the risk of flap-related complication with breast volume >1000 cc [15]. These different findings may be related mostly to the method of the glandular specimen measurement. Moreover radiotherapy influence on complication rate was not evaluated and the influence of the individual surgeon's technique should be investigated further in larger studies.

Implant volume was a positive predictor of complication for every 100 g of volume increase. Chirappapha et al observed a trend of higher risk of necrosis in larger volume of prosthesis inserted for the reconstruction, even if it was not significant [9]. Santanelli et al noted that prosthesis weight >468 g was significant and thus considered a clinical selection criterion, with a 48% increase in risk of skin flap ischemia [16].

Although the literature has shown that smoking status is an important risk factor for NAC necrosis [17,18], the smoking history was not related to mastectomy skin flap and NAC complication. The number of smoker patients was too small in the current study to determine a significant association.

BMI (>25.1 kg/m^2) was not found as prognostic factor for complication as previous observations [19–21]. This can be attributed to the fact that NSM is usually offered to patients with small breasts accompanied, usually, by a low BMI therefore it might not have been detected as a risk factor due to a sample where almost no patient was obese.

Twardella et al claimed that patients with BMI above 25.1 have an increased risk of skin toxicity of 2.86 (95% CI: 1.74–4.73) in comparison to patients with BMI below 25.1 [22]. One might suppose that increased BMI may predispose to compromised sub-dermal perfusion and flap necrosis due to a larger flap surface area, and in addition, obeses are likely to have associated microvascular diseases.

There is evidence that delaying expander-implant exchange for at least 6 months after the completion of post-mastectomy radiation therapy can significantly reduce

expander-implant failure [23]. Baumann et al observed that an interval of 12 months between the completion of post-mastectomy radiation therapy and delayed abdominal free flap breast reconstruction will likely minimize complications and optimize outcomes in free flap breast reconstruction in patients receiving postmastectomy radiation [24]. These reports suggested that waiting longer time following radiotherapy to carry out implant or autologous reconstruction can result in lower rate of complication. In the current study, patients who had undergone NSM within 5 years from radiotherapy were more subject for complications (63.6%) rather than after 5 years (33.4%), even if it was not statistical significant ($p > .05$). Certainly, surgeons cannot delay mastectomy to a more optimal timing if a patient has a recurrence or a new cancer.

Conclusion

This retrospective review demonstrated that NSM followed by implant-based and autologous reconstruction had a relative high rate of complications (13.5%). Limitations of the study were related to NSM candidate patients who did not have breast ptosis higher than the second degree, to the number of smoker and irradiated patients that was too small to determine a significant association. Finally NSM was offered only to women with small to medium breast size.

Radiotherapy and implant volume resulted positive predictors for complications. Even if no correlation was observed between type of reconstruction and complications, from our experience a complication management may be easier in autologous reconstruction than in the implant one. Whenever potential risk factors are identified, it should be taken into consideration to change the type of mastectomy avoiding major complication such as reconstruction failure, long hospital stay and a delayed secondary salvage procedure.

Disclosure statement

The authors declare that they have no conflict of interest.

References

1. Petit JY, Veronesi U, Orecchia R, et al. Risk factors associated with recurrence after nipple-sparing mastectomy for invasive and intraepithelial neoplasia. Ann Oncol 2012;23:2053–8.
2. de Alcantara Filho P, Capko D, Barry JM, et al. Nipple-sparing mastectomy for breast cancer and risk-reducing surgery: the Memorial Sloan-Kettering Cancer Center experience. Ann Surg Oncol 2011;18:3117–22.
3. Jensen JA, Orringer JS, Giuliano AE. Nipple-sparing mastectomy in 99 patients with a mean follow-up of 5 years. Ann Surg Oncol 2011;18:1665–70.
4. Spear SL, Willey SC, Feldman ED, et al. Nipple-sparing mastectomy for prophylactic and therapeutic indications. Plast Reconstr Surg 2011;128:1005–14.
5. Komorowski AL, Zanini V, Regolo L, et al. Necrotic complications after nipple- and areola-sparing mastectomy. World J Surg 2006; 30:1410–13.
6. Chen CM, Disa JJ, Sacchini V, et al. Nipple-sparing mastectomy and immediate tissue expander/implant breast reconstruction. Plast Reconstr Surg 2009;124:1772–80.
7. Alperovich M, Tanna N, Samra F, et al. Nipple-sparing mastectomy in patients with a history of reduction mammaplasty or mastopexy: How safe is it? Plast Reconstr Surg 2013;131:962–7.
8. Colwell AS, Tessler O, Lin AM, et al. Breast reconstruction following nipple-sparing mastectomy: predictors of complications, reconstruction outcomes, and 5-year trends. Plast Reconstr Surg 2014;133:496–506.
9. Chirappapha P, Petit JY, Rietjens M, et al. Nipple sparing mastectomy: does breast morphological factor related to necrotic complications? Plast Reconstr Surg Glob Open 2014;2:e99.
10. Robertson SA, Rusby JE, Cutress RI. Determinants of optimal mastectomy skin flap thickness. Br J Surg 2014;101:899–911.
11. Chun YS, Verma K, Rosen H, et al. Use of tumescent mastectomy technique as a risk factor for native breast skin flap necrosis following immediate breast reconstruction. Am J Surg 2011;201: 160–5.
12. Iwahira Y, Nagase T, Nakagami G, et al. Histopathological comparisons of irradiated and nonirradiated breast skin from the same individuals. J Plast Reconstr Aesthet Surg 2012;65: 1496–505.
13. Woerdeman LA, Hage JJ, Hofland MM, Rutgers EJ. A prospective assessment of surgical risk factors in 400 cases of skin-sparing mastectomy and immediate breast reconstruction with implants to establish selection criteria. Plast Reconstr Surg 2007;119:455–63.
14. Munhoz AM, Aldrighi CM, Montag E, et al. Clinical outcomes following nipple-areola-sparing mastectomy with immediate implant-based breast reconstruction: a 12-year experience with an analysis of patient and breast-related factors for complications. Breast Cancer Res Treat 2013;140:545–55.
15. Nahabedian MY, Momen B, Galdino G, Manson PN. Breast reconstruction with the free TRAM or DIEP flap: patient selection, choice of flap, and outcome. Plast Reconstr Surg 2002;110:466–75. Discussion 476.
16. Santanelli F, Longo B, Sorotos M, et al. Flap survival of skin-sparing mastectomy type IV: a retrospective cohort study of 75 consecutive cases. Ann Surg Oncol 2013;20:981–9.
17. Algaithy ZK, Petit JY, Lohsiriwat V, et al. Nipple sparing mastectomy: can we predict the factors predisposing to necrosis? Eur J Surg Oncol 2012;38:125–9.
18. Garwood ER, Moore D, Ewing C, et al. Total skin-sparing mastectomy: complications and local recurrence rates in 2 cohorts of patients. Ann Surg 2009;249:26–32.
19. Davies K, Allan L, Roblin P, et al. Factors affecting post-operative complications following skin sparing mastectomy with immediate breast reconstruction. Breast 2011;20:21–5.
20. Crowe JP, Jr, Kim JA, Yetman R, et al. Nipple-sparing mastectomy: technique and results of 54 procedures. Arch Surg 2004;139: 148–50.
21. Longo B, Laporta R, Sorotos M, et al. Total breast reconstruction using autologous fat grafting following nipple-sparing mastectomy in irradiated and non-irradiated patients. Aesthetic Plast Surg 2014;38:1101–8.
22. Twardella D, Popanda O, Helmbold I, et al. Personal characteristics, therapy modalities and individual DNA repair capacity as predictive factors of acute skin toxicity in an unselected cohort of breast cancer patients receiving radiotherapy. Radiother Oncol 2003; 69:145–53.
23. Peled AW, Foster RD, Esserman LJ, et al. Increasing the time to expander-implant exchange after postmastectomy radiation therapy reduces expander-implant failure. Plast Reconstr Surg 2012;130:503–9.
24. Baumann DP, Crosby MA, Selber JC, et al. Optimal timing of delayed free lower abdominal flap breast reconstruction after postmastectomy radiation therapy. Plast Reconstr Surg 2011;127: 1100–6.